

Gracias

Este documento de Powerpoint contiene
la imagen que ha solicitado

Aviso de derechos reservados de autor

Todos los materiales del servicio online, incluyendo, sin limitación, texto, imágenes, gráficos y otros archivos y la selección y el arreglo de esto, son materiales con derechos de autor de Ovid o de sus licenciadores, todos los derechos reservados. A excepción del uso autorizado especificado arriba, usted no puede copiar, modificar o distribuir los materiales del servicio online. Usted no puede reflejar ningún material contenido en este servicio online o en cualquier otro servidor. Cualquier uso no autorizado de cualquier material contenido en este servicio online puede violar leyes de Derechos de Autor, las leyes de marca registrada, las leyes de privacidad y publicidad y las regulaciones y los estatutos de las comunicaciones.



Surgical repair of congenital mitral valve malformations in infancy and childhood: A single-center 36-year experience.

Stellin, Giovanni; Padalino, Massimo; MD, PhD; Vida, Vladimiro; MD, PhD; Boccuzzo, Giovanna; Orru, Emanuele; Biffanti, Roberta; Milanese, Ornella; Mazzucco, Alessandro

Journal of Thoracic & Cardiovascular Surgery.
140(6):1238-1244, December 2010.
DOI: 10.1016/j.jtcvs.2010.05.016.x

Figure. no caption available.

Table 1

Surgical repair of congenital mitral valve malformations in infancy and childhood: A single-center 36-year experience.

Stellin, Giovanni; Padalino, Massimo; MD, PhD; Vida, Vladimiro; MD, PhD; Boccuzzo, Giovanna; Orru, Emanuele; Biffanti, Roberta; Milanese, Ornella; Mazzucco, Alessandro

Journal of Thoracic & Cardiovascular Surgery. 140(6):1238-1244, December 2010.

DOI: 10.1016/j.jtcvs.2010.05.016.x

MV malformations	No. of patients
MV regurgitation (or prevalent)	48
Type I (normal leaflet motion)	32
Annular dilatation	12
Cleft anterior leaflet	18
Leaflet defect	2
Type II (leaflet prolapse)	9
Elongated chordae	9
Type III (restricted leaflet motion)	7
Type A (normal papillary muscles)	
Papillary muscles commissure fusion	1
Short chordae	2
Type B (abnormal papillary muscles)	
Parachute MV	2
Hammock MV	2
MV stenosis (or prevalent)	45
Type A (normal papillary muscles)	24
Papillary muscle commissure fusion	14
Supravalvular membrane	7
Double-orifice MV	3
Type B (abnormal papillary muscles)	21
Parachute MV	10
Hammock MV	4
Shone complex	5
Arcade MV	2
Total	93

CMV, Congenital mitral valve; MV, mitral valve.

Technique	No. of patients
Papillary muscle splitting	35
Cleft closure	21
Annuloplasty (Kaye, Paneth)	20
Supravalvular ring excision	16
Commissurotomy	15
Chordal shortening	9
Ring annuloplasty	6
Commissuroplasty	4
Accessory orifice closure	2

Table 2

Cardiac anomaly	No. of patients	Patients with previous surgical intervention
Subaortic stenosis	31	7
VSD	23	0
Aortic coarctation	19	19
Aortic regurgitation	4	0
Pulmonary stenosis	3	2
Abnormal LAD origin	2	0
Other	11	2*

MV, Mitral valve; VSD, ventricular septal defect; LAD, left anterior descending. *Two patients had patent ductus arteriosus closure at birth.

Surgical repair of congenital mitral valve malformations in infancy and childhood: A single-center 36-year experience.

Stellin, Giovanni; Padalino, Massimo; MD, PhD; Vida, Vladimiro; MD, PhD; Boccuzzo, Giovanna; Orru, Emanuele; Biffanti, Roberta; Milanese, Ornella; Mazzucco, Alessandro

Journal of Thoracic & Cardiovascular Surgery.
140(6):1238-1244, December 2010.
DOI: 10.1016/j.jtcvs.2010.05.016.x

Table 2 List of patients with associated cardiac anomalies in the complex group and those in whom repair of cardiac anomaly was performed before MV repair

Table 3

Technique	No. of patients
Papillary muscle splitting	35
Cleft closure	21
Annuloplasty (Kaye, Paneth)	20
Supravalvular ring excision	16
Commissurotomy	15
Chordal shortening	9
Ring annuloplasty	6
Commissuroplasty	4
Accessory orifice closure	2

Surgical repair of congenital mitral valve malformations in infancy and childhood: A single-center 36-year experience.

Stellin, Giovanni; Padalino, Massimo; MD, PhD; Vida, Vladimiro; MD, PhD; Boccuzzo, Giovanna; Orru, Emanuele; Biffanti, Roberta; Milanese, Ornella; Mazzucco, Alessandro

Journal of Thoracic & Cardiovascular Surgery.
140(6):1238-1244, December 2010.
DOI: 10.1016/j.jtcvs.2010.05.016.x

Table 3 Surgical techniques used to achieve mitral valve repair

Table 4

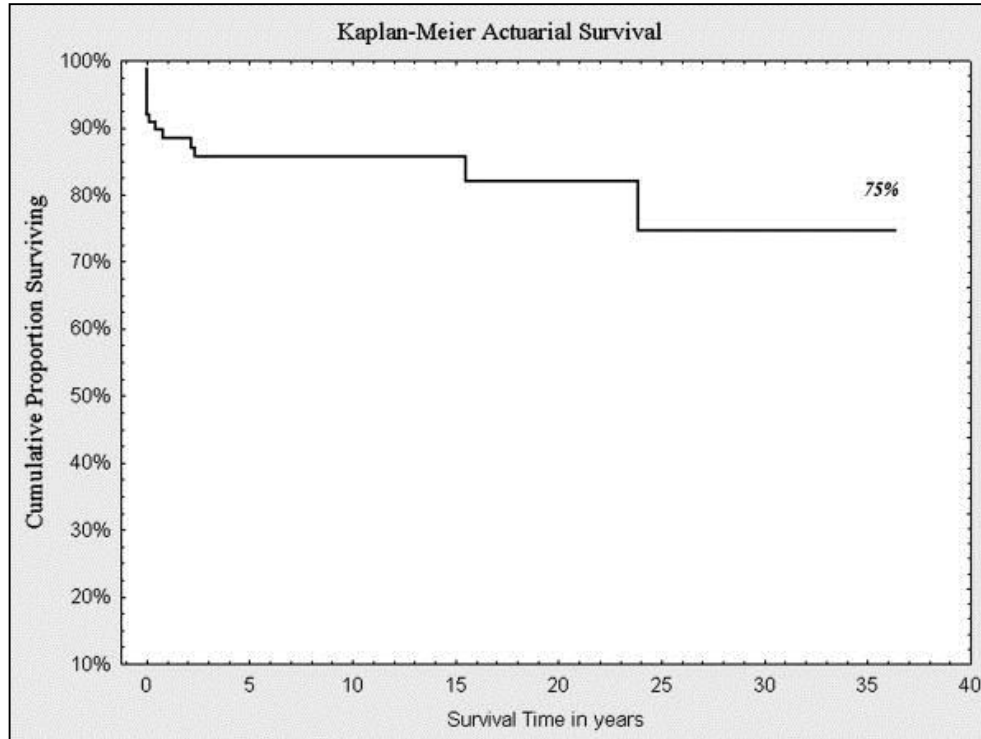
Complications	No. of patients	Exitus
LCO syndrome	4	4
Bleeding	4	2
Complete AV block	2	0
Pericardial effusion	1	0
Pleural effusion	1	0
Mediastinitis/septic shock	1	1
Postpericardiotomy syndrome	1	0

LCO, Low cardiac output; *AV*, atrioventricular.

Surgical repair of congenital mitral valve malformations in infancy and childhood: A single-center 36-year experience.
 Stellin, Giovanni; Padalino, Massimo; MD, PhD; Vida, Vladimiro; MD, PhD; Boccuzzo, Giovanna; Orru, Emanuele; Biffanti, Roberta; Milanese, Ornella; Mazzucco, Alessandro
 Journal of Thoracic & Cardiovascular Surgery.
 140(6):1238-1244, December 2010.
 DOI: 10.1016/j.jtcvs.2010.05.016.x

Table 4 List of patients with early postoperative complications that led to early death

Figure 1



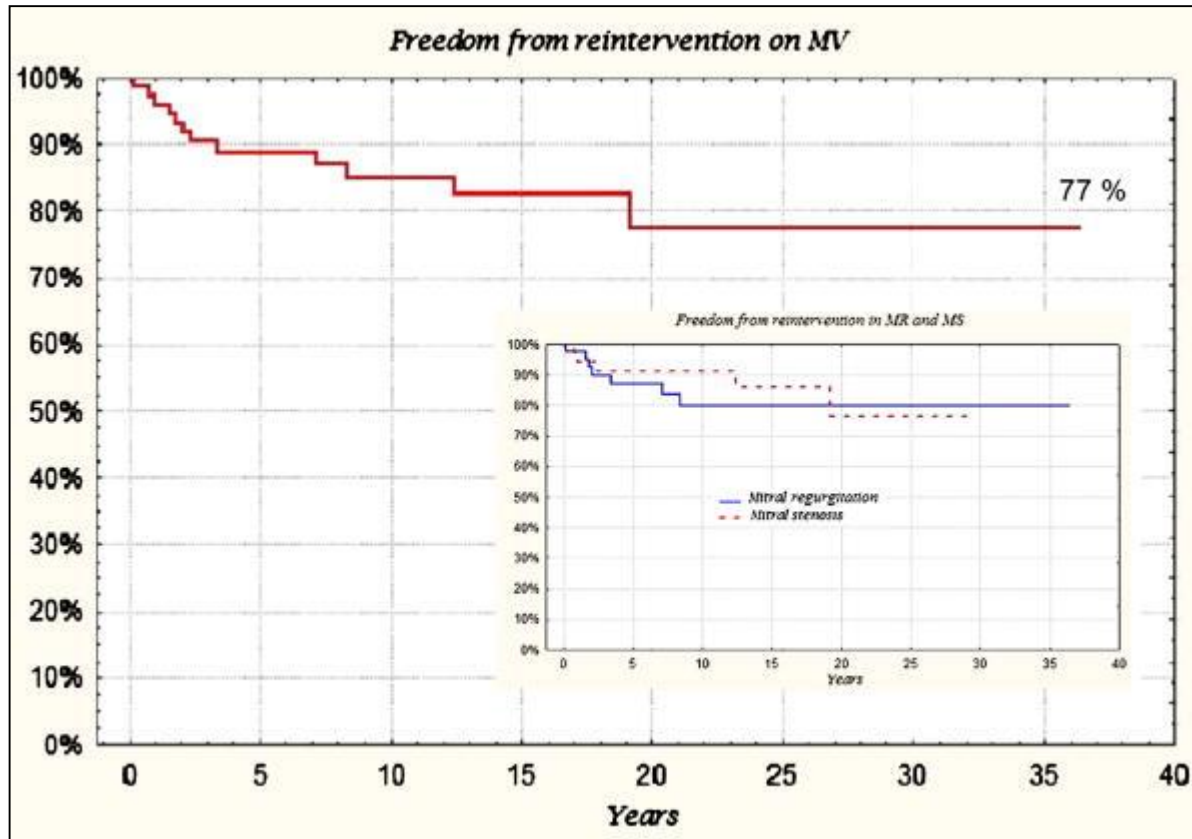
Surgical repair of congenital mitral valve malformations in infancy and childhood: A single-center 36-year experience.

Stellin, Giovanni; Padalino, Massimo; MD, PhD; Vida, Vladimiro; MD, PhD; Boccuzzo, Giovanna; Orru, Emanuele; Biffanti, Roberta; Milanesi, Ornella; Mazzucco, Alessandro

Journal of Thoracic & Cardiovascular Surgery.
140(6):1238-1244, December 2010.
DOI: 10.1016/j.jtcvs.2010.05.016.x

Figure 1 Kaplan-Meier analysis shows that overall survival is 75% at 36 years.

Figure 2



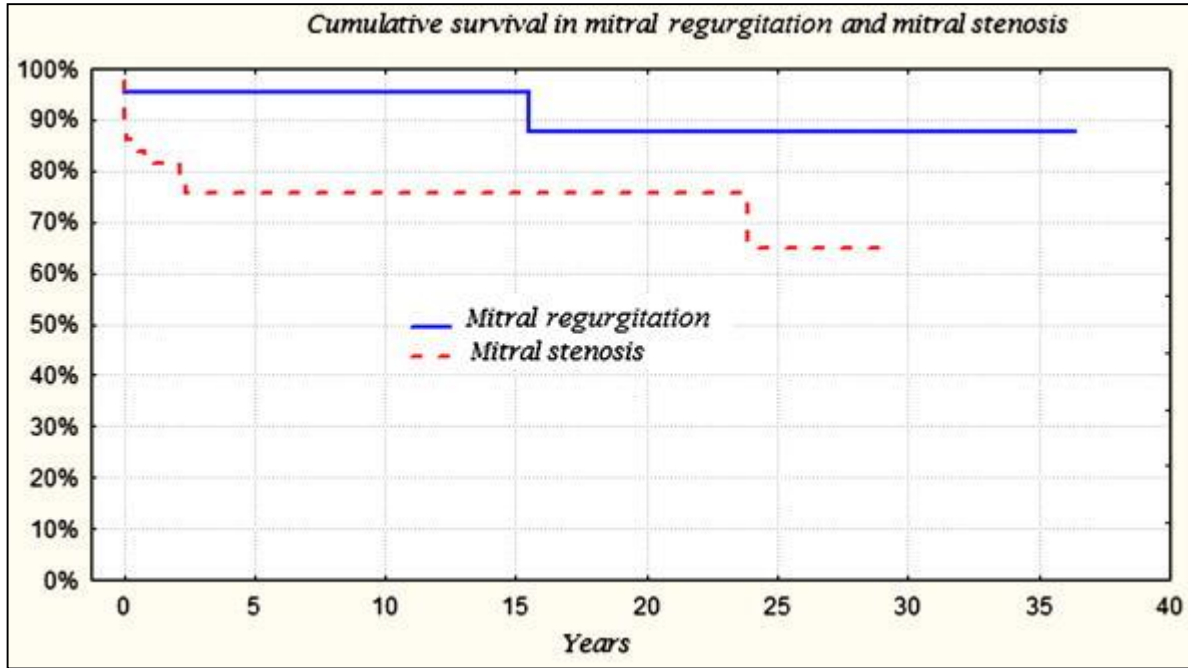
Surgical repair of congenital mitral valve malformations in infancy and childhood: A single-center 36-year experience.

Stellin, Giovanni; Padalino, Massimo; MD, PhD; Vida, Vladimiro; MD, PhD; Boccuzzo, Giovanna; Orru, Emanuele; Biffanti, Roberta; Milanese, Ornella; Mazzucco, Alessandro

Journal of Thoracic & Cardiovascular Surgery.
140(6):1238-1244, December 2010.
DOI: 10.1016/j.jtcvs.2010.05.016.x

Figure 2 Kaplan-Meier analysis shows that freedom from reoperation on the mitral valve is 77% at 36 years.

Figure 3



Surgical repair of congenital mitral valve malformations in infancy and childhood: A single-center 36-year experience.

Stellin, Giovanni; Padalino, Massimo; MD, PhD; Vida, Vladimiro; MD, PhD; Boccuzzo, Giovanna; Orru, Emanuele; Biffanti, Roberta; Milanesi, Ornella; Mazzucco, Alessandro

Journal of Thoracic & Cardiovascular Surgery.
140(6):1238-1244, December 2010.
DOI: 10.1016/j.jtcvs.2010.05.016.x

Figure 3 Kaplan-Meier analysis shows that survival estimates for patients with mitral stenosis are significantly lower than for patients with mitral regurgitation (P = .021; OR, 4.698).

Outcomes	Variables				
	Complex MV (OR)	MV stenosis (OR)	Parachute MV (OR)	Before 1984 (OR)	Age, y (OR)
Any adverse outcome	3.173	<i>2.520</i>	-	-	-
Early death	-	-	<i>7.122</i>	18.40	0.636
Late death	-	<i>6.973</i>	-	-	-
Preoperative medical therapy	-	-	<i>4.889</i>	-	-
Reoperation on MV	-	-	<i>6.817</i>	-	-
Operation on MV before 1 y of age	-	<i>7.219</i>	-	-	-
Heart failure at follow-up	-	-	<i>6.100</i>	-	-
Arrhythmias	-	-	<i>6.377</i>	4.744	-

Variables significant at a level of .05 < P < .1 are shown in *italics*. MV, Mitral valve; OR, odd ratio.

Surgical repair of congenital mitral valve malformations in infancy and childhood: A single-center 36-year experience.
 Stellin, Giovanni; Padalino, Massimo; MD, PhD; Vida, Vladimiro; MD, PhD; Boccuzzo, Giovanna; Orru, Emanuele; Biffanti, Roberta; Milanese, Ornella; Mazzucco, Alessandro
 Journal of Thoracic & Cardiovascular Surgery. 140(6):1238-1244, December 2010.
 DOI: 10.1016/j.jtcvs.2010.05.016.x

